

Dr AM Thirugnanam, MD, FSCAI, Ph.D., Senior Interventional Cardiologist, India

**ANOMALOUS LEFT MAIN IN STEMI, LAD
AND RCA ARE CULPRIT VESSELS,
SINGLE VESSEL WAS STENTED BY FFR**

65 years old lady with evolving AWWMI and IWMI

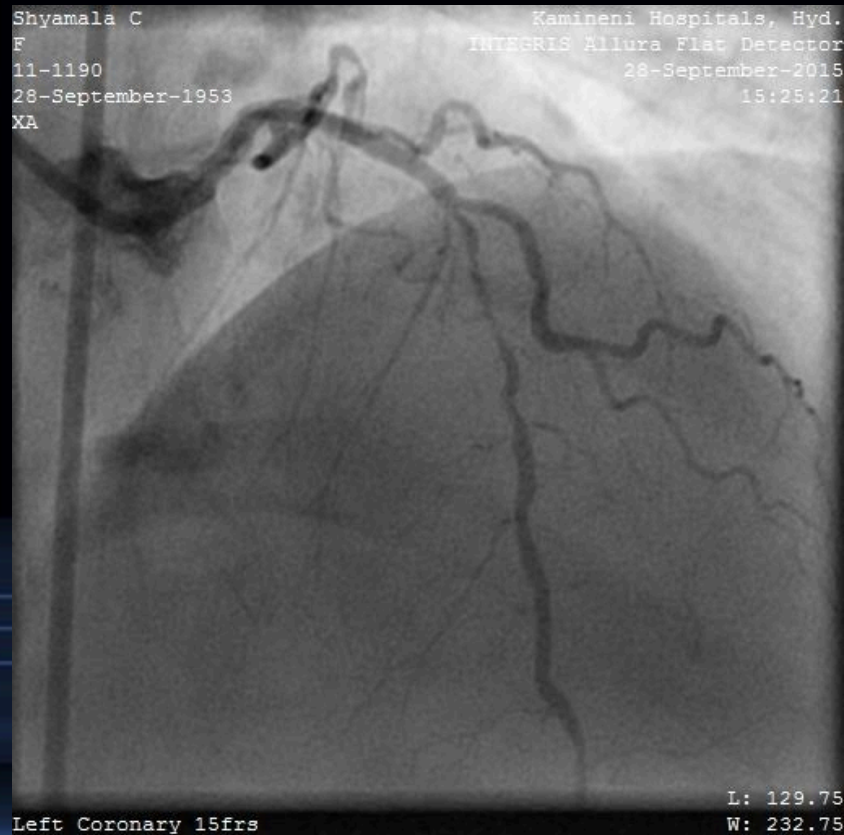
- History of DM, DLP and HT for 25 years, Lost her right upper limb in an accident up to shoulder.
- No significant history
- Had STEMI and not thrombolised
- Referred to rescue PCI from rural cardiologist
- Crescendo angina not relieved by all important anti angina drugs

Pre-cath evaluation

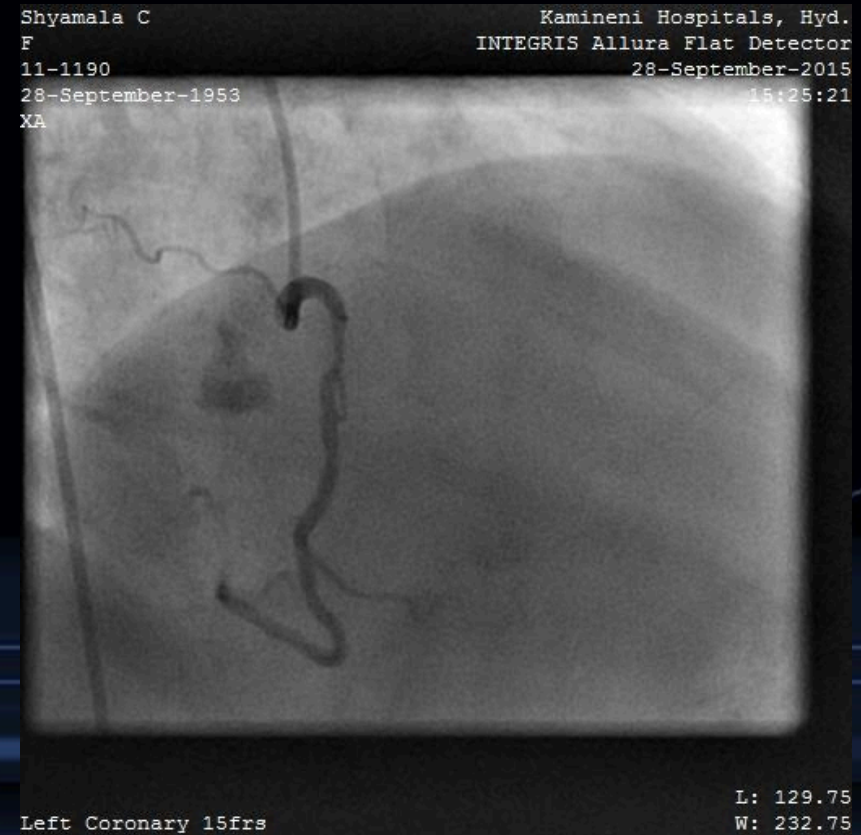
- BP-80/100mmhg, HR-120/min, Lungs- mild bilateral crepitation, RR-20/min, Saturation-95% ARA,
- ECG- ST elevation in V1-V6 and II, III, AvF
- LVEF-35%, CtnI-1500ng/dl, Pro BNP-1900,
- RBS-235mg/dl, urea-45mg/dl, creatinine-1.6mg/dl,
- Other biochemistry values are normal

Angiogram by RF route, LAD-90%, RCA-80%

Left system-anomalous



RCA tortuous



Difficulty in engaging LM

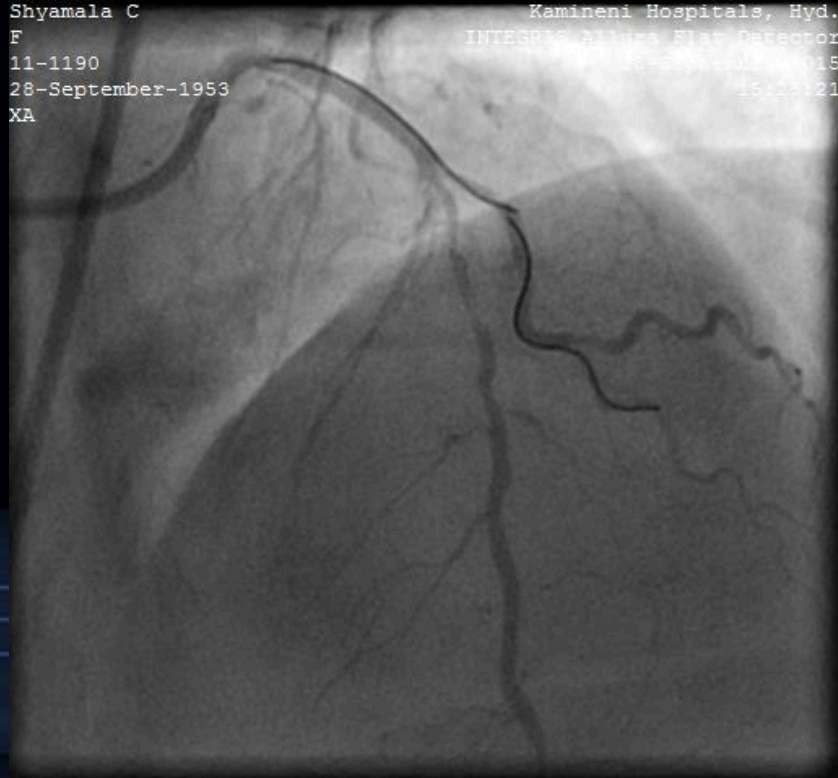
- We used EBU, Amplatz, XB, and Voda guide catheters but unable to seat LM and frequently developed damping and hypotension. We decided to go for wire anchoring with JL-4 and guide flotation method
- Parked one fielder XT in diagonal and BMW in LAD
- Predilated with 2/10mm balloon

Wire anchoring and guide flotation

Diagonal wiring and LAD

Shyamala C
F
11-1190
28-September-1953
XA

Kamineni Hospitals, Hyd.
INTEGRIS Allura Flat Detector
15:21:21



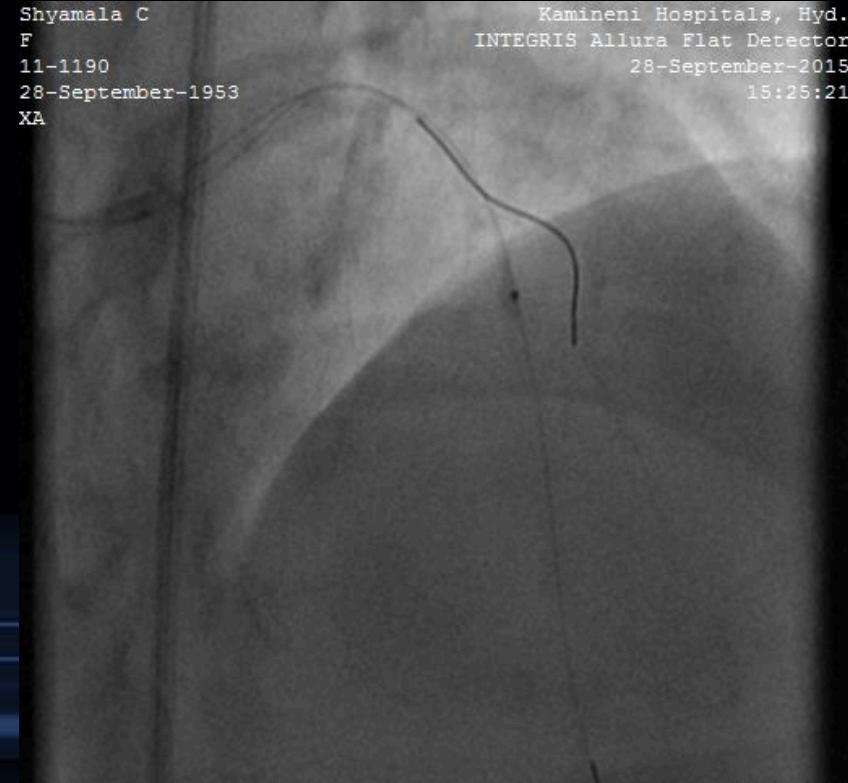
Left Coronary 15frs

L: 129.75
W: 232.75

Dilating with 2/10mm balloon

Shyamala C
F
11-1190
28-September-1953
XA

Kamineni Hospitals, Hyd.
INTEGRIS Allura Flat Detector
28-September-2015
15:25:21



Left Coronary 15frs

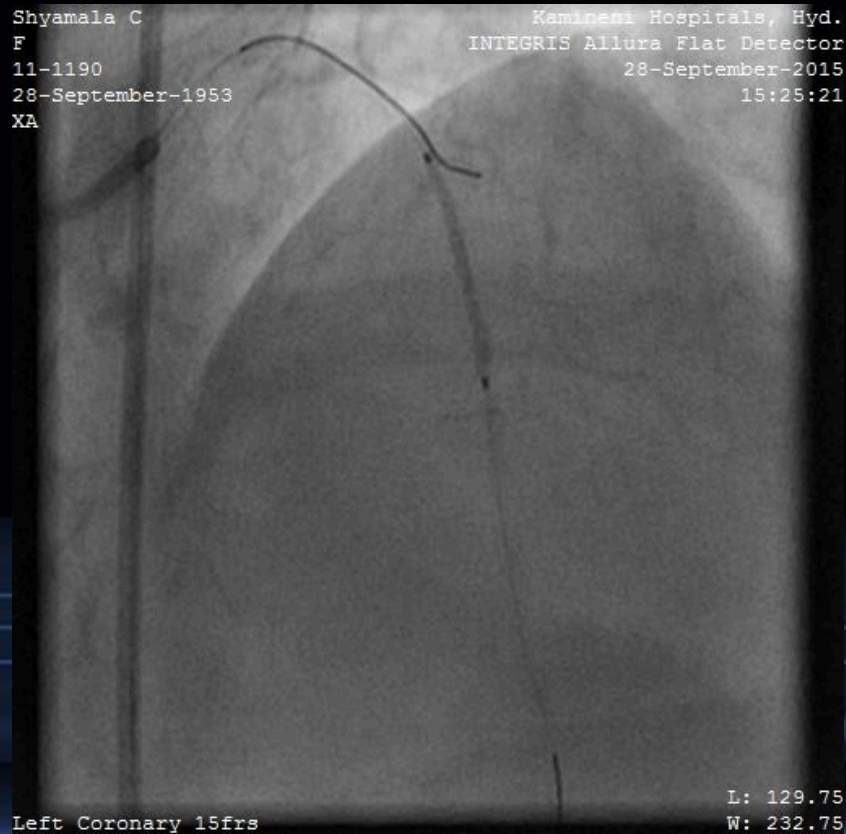
L: 129.75
W: 232.75

Final deployment of stent-Xience expedition

LAD stent positioning

Shyamala C
F
11-1190
28-September-1953
XA

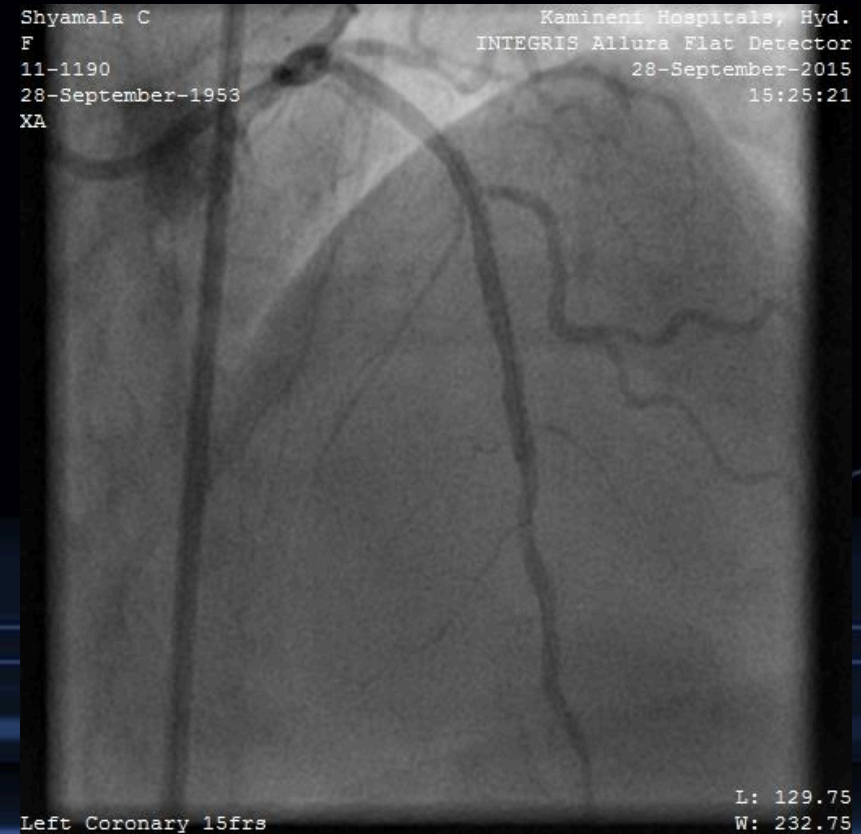
Kamineni Hospitals, Hyd.
INTEGRIS Allura Flat Detector
28-September-2015
15:25:21



Final result

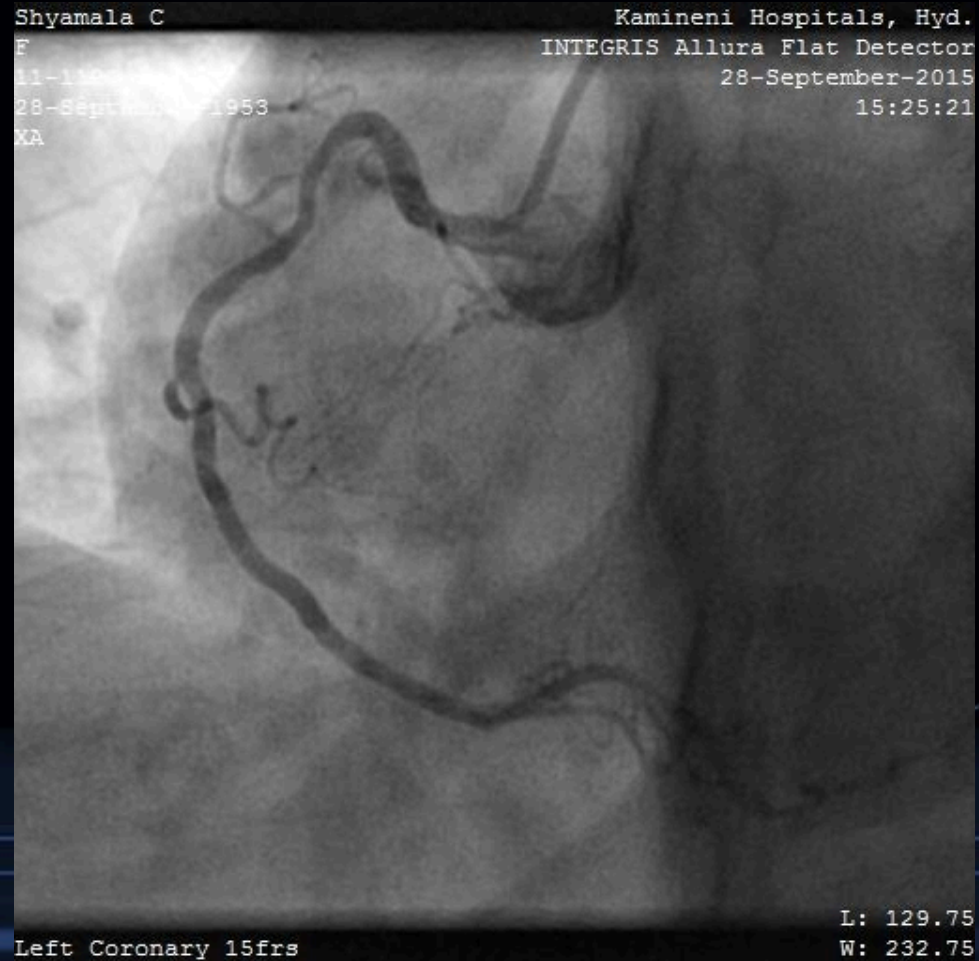Shyamala C
F
11-1190
28-September-1953
XA

Kamineni Hospitals, Hyd.
INTEGRIS Allura Flat Detector
28-September-2015
15:25:21



FFR of RCA showed 0.90

FFR guided RCA lesion
avoided multiple culprit vessel
stenting in ACS



Drugs in peri procedure and post procedure

- 600mg clopidogrel, ASA-325 mg, Atorvastatin-80mg and bolus 10 ml of Abciximab were given before procedure
- Bivalirudin anticoagulation was given bolus and infusion based on weight

Take Home message

- Multiple vessel STEMI is tough to handle in anomalous coronary anatomy
- FFR will help to take best decision in culprit vessel PTCA