

Takayasu Arteritis in 15 years old Girl with BSFA thrombosis

Dr AM Thirugnanam
Sr. Interventional Cardiologist
www.cardiologycourse.com,
www.bestmedicalschoollonline.com, Hyderabad, Telangana,
India.

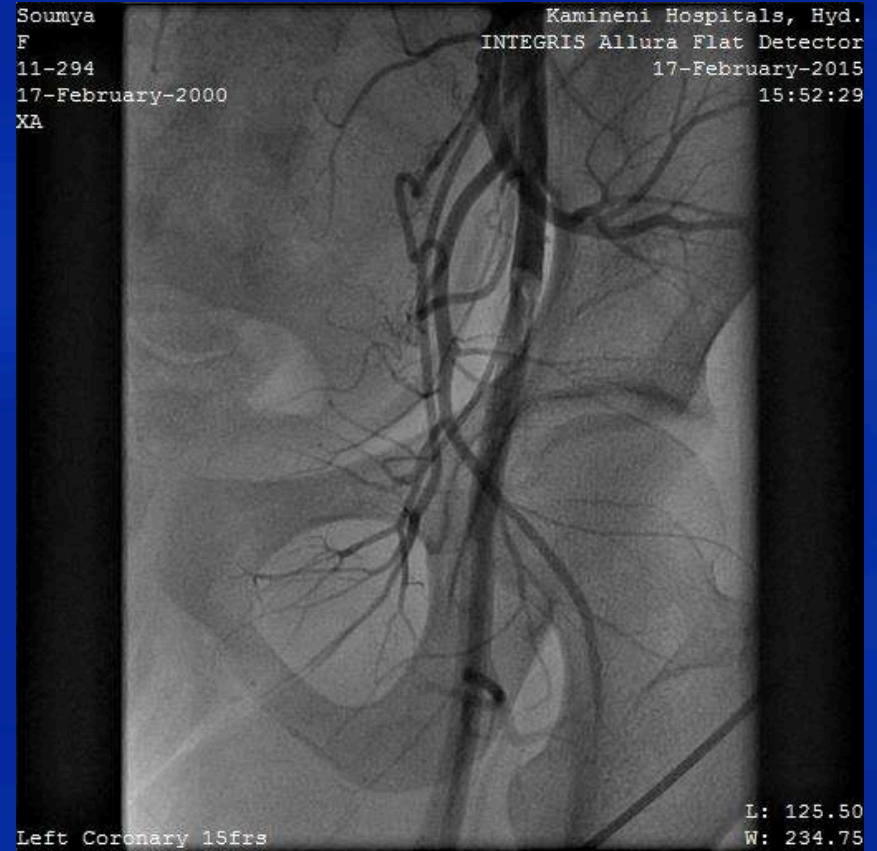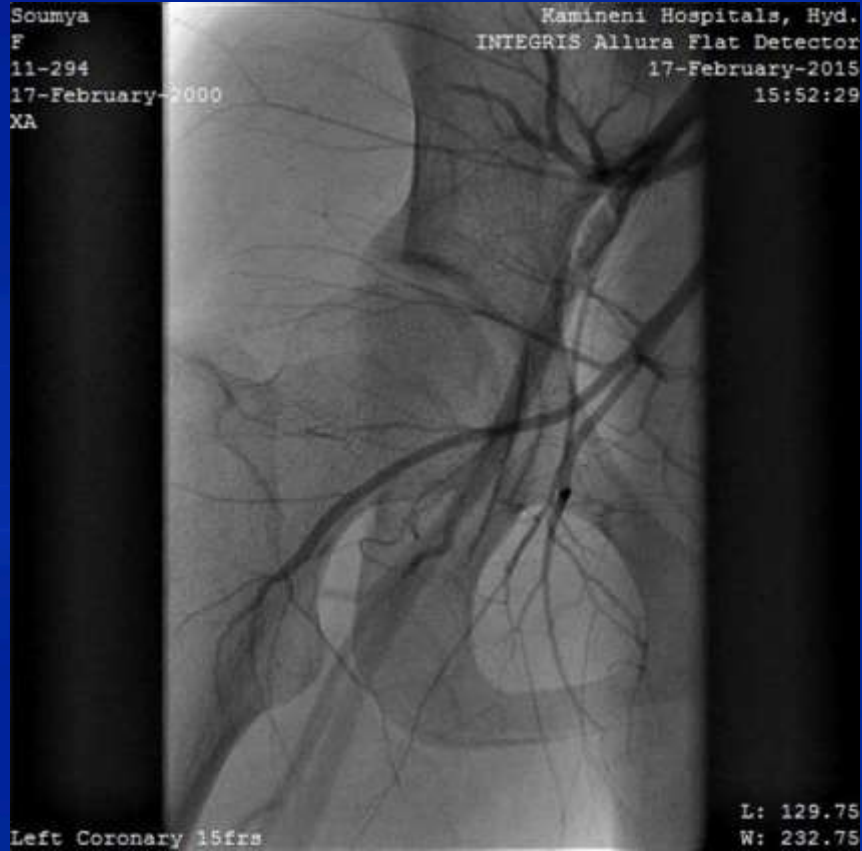
CASE HISTORY / RISK FACTOR

- 15 years old girl had undiagnosed Takayasu Arteritis accelerated hypertension.
- She was treated outside for hypertension where they were unable to bring under control.
- Both the legs were discolored.
- Severe claudication, unable to walk for even 5 mts
- Bilateral absence of femoral pulses

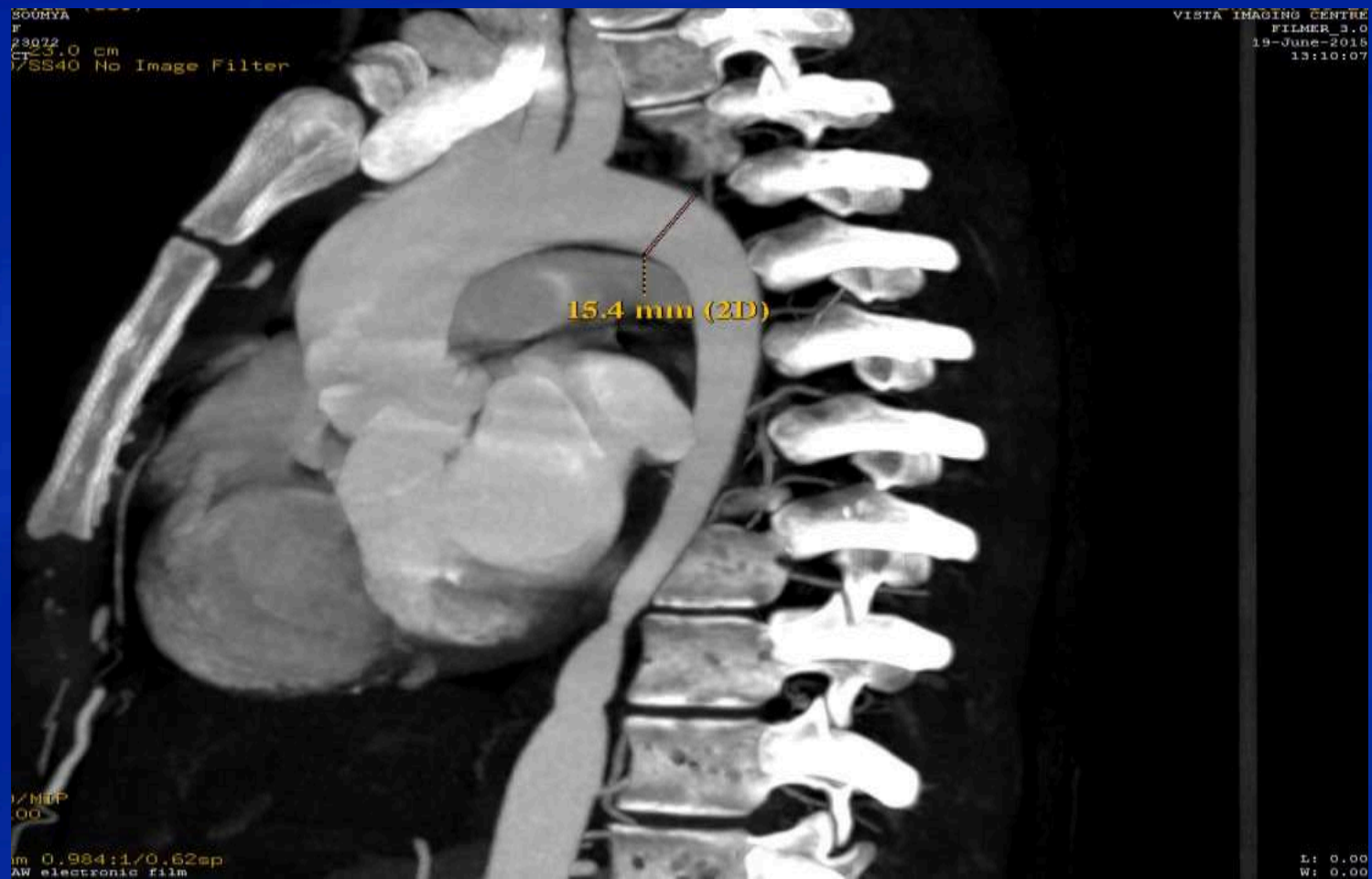
Investigations

- Examination: ECG-NSR, Echocardiogram-N, Thyroid-N, Collagen profile-N, hsCRP-26, other basic biochemistry were normal
- Physical examination: normal cardiac sounds, chest-clear, RAP-110/220mmhg, LAP-110/230mmhg, absence of bilateral femoral pulses and lower limb pulses

Peripheral angiogram



CT-aortogram-Type-2b



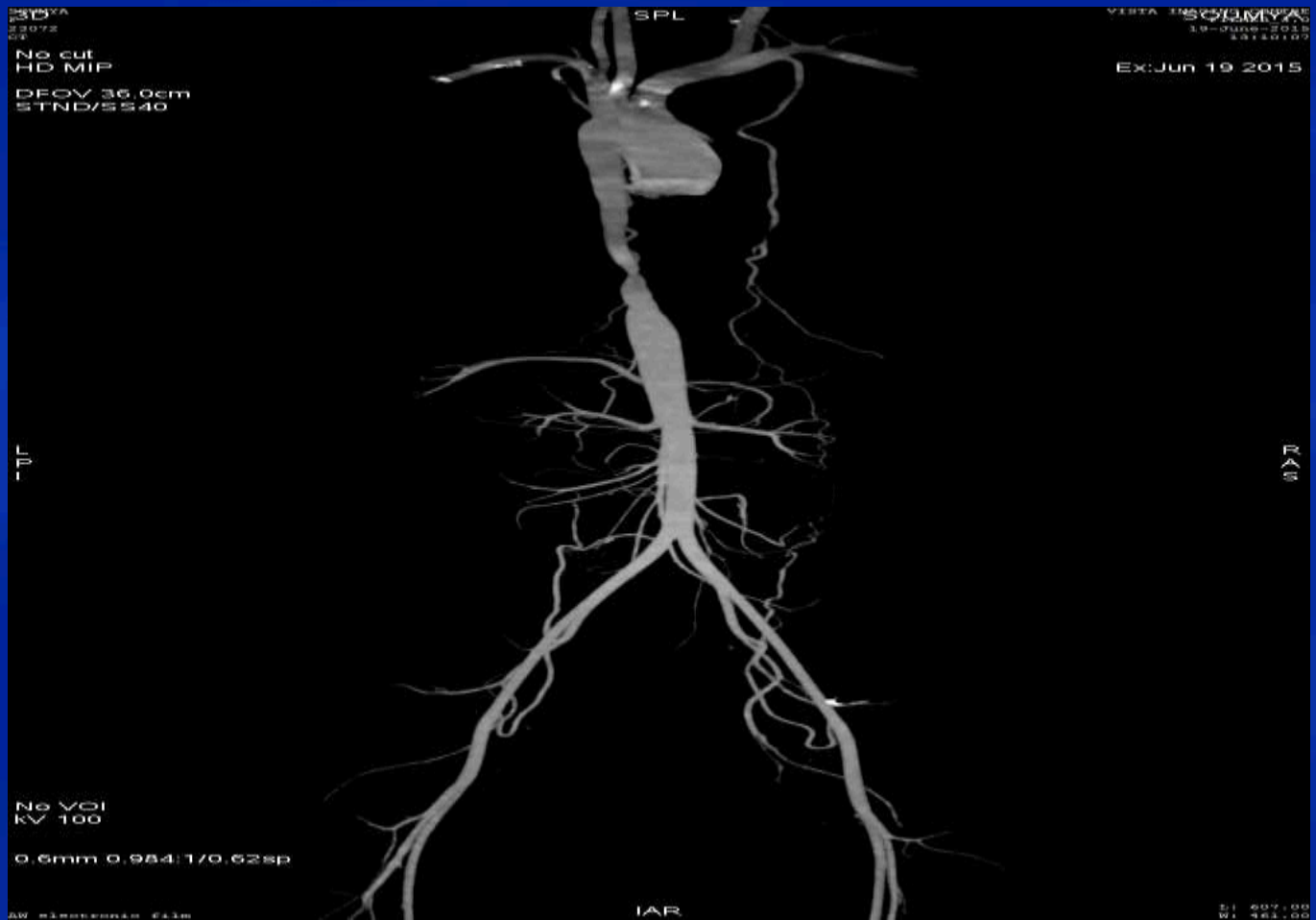
Takayasu Angiographic Classification

- Type I- Branches of Aortic Arch
- Type IIa- Ascending Aorta, aortic arch and its branches
- Type IIb- Type IIa region plus thoracic descending aorta
- Type III- Thoracic descending aorta, abdominal aorta and renal arteries or a combination
- Type IV- Abdominal aorta, renal arteries or both
- Type V- Entire aorta and its branches

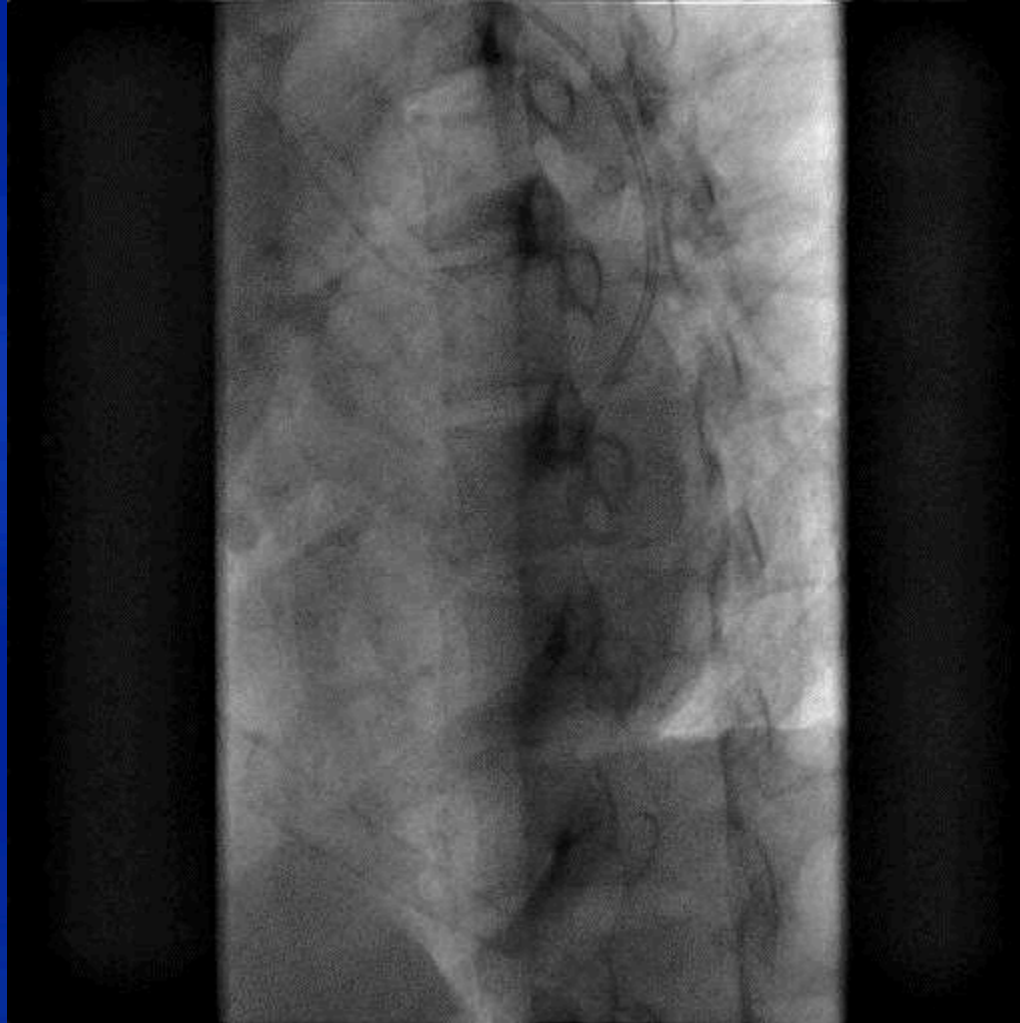
Stage-1 treatment

- 1- treatment for thrombosis-Patient was given SC and oral anticoagulation for 4 weeks. Repeated imaging showed dissolved thrombus in SFA

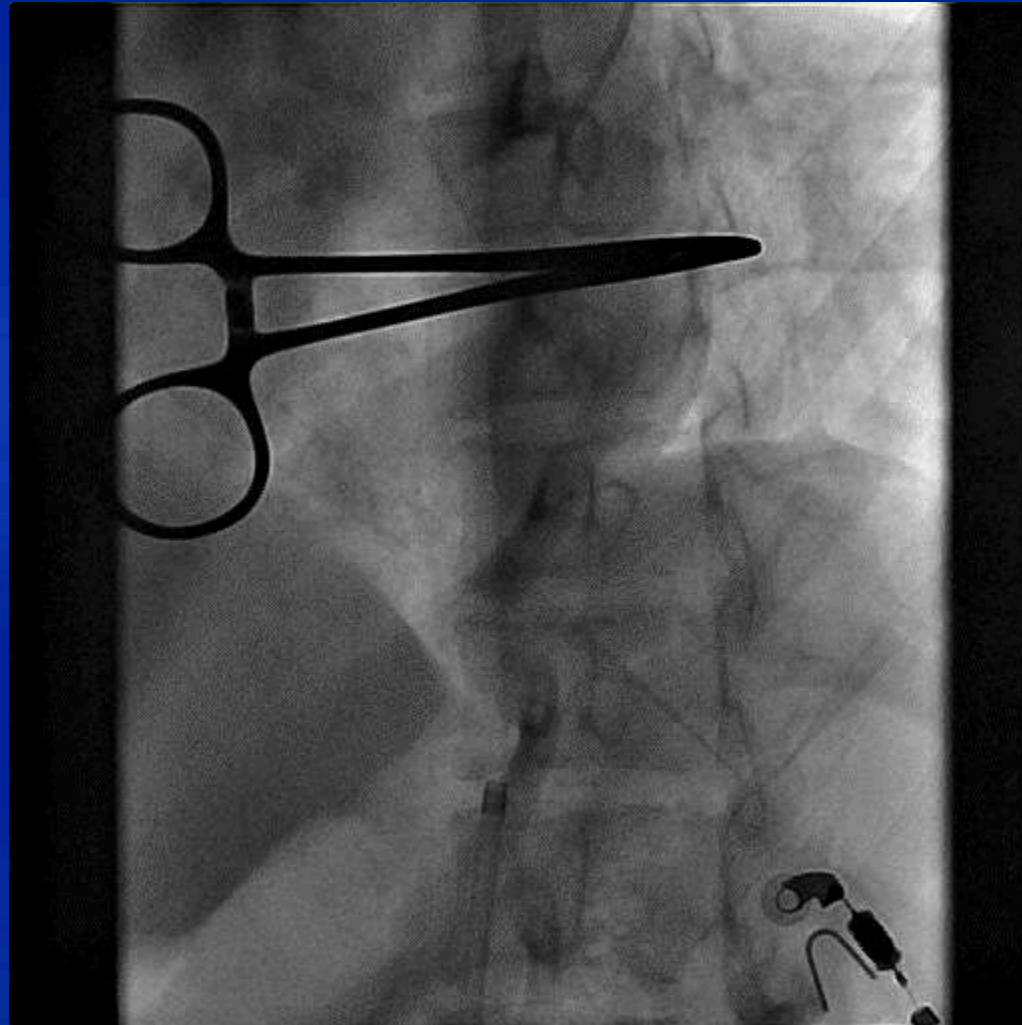
Resolved Bilateral SFA thrombosis



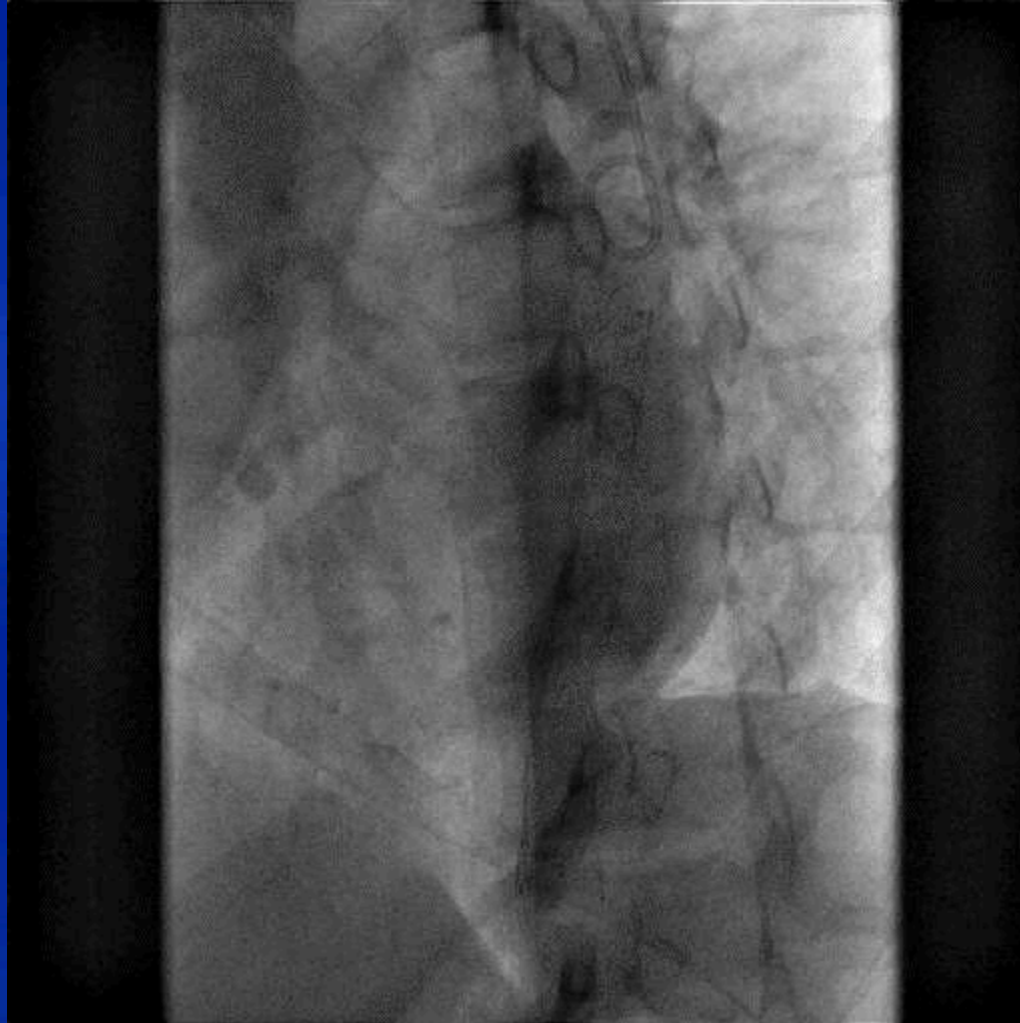
Pigtail in Ascending Aorta through RR



7 Fr sheath in RFA



Final results



Take home message

- In Takayasu arteritis, thrombosis and descending aorta stenting make us tough
- Proper skills in aorta procedure only can avoid unnecessary complications.
- Not to go where the pulses are absent, CT guided approach is the safest and gold standard procedure to avoid procedure related complications